

Hallux rigidus: Joint preserving alternatives to arthrodesis - a review of the literature

Hans Polzer, Sigmund Polzer, Mareen Brumann, Wolf Mutschler, Markus Regauer

Hans Polzer, Mareen Brumann, Wolf Mutschler, Markus Regauer, Munich University Hospital, Foot and Ankle Surgery, Department of Trauma Surgery-Campus Innenstadt, 80336 Munich, Germany

Sigmund Polzer, Department of Hand, Ellbow and Footsurgery, ATOS Clinic Heidelberg, 69115 Heidelberg, Germany

Author contributions: Polzer H and Polzer S conceived designed and drafted the manuscript; Brumann M and Regauer M acquired and analysed the literature and finalized the manuscript; Mutschler W gave substantial input concerning the conception and design and critically revised the manuscript; all authors gave final approval of the article to be published.

Correspondence to: Hans Polzer, MD, Munich University Hospital, Ludwig-Maximilians-University, Foot and Ankle Surgery, Department of Trauma Surgery-Campus Innenstadt, Nussbaumstrasse 20, 80336 Munich,

Germany. hans.polzer@med.uni-muenchen.de

Telephone: +49-89-51602511 Fax: +49-89-51602662

Received: October 2, 2013 Revised: November 3, 2013

Accepted: November 15, 2013

Published online: January 18, 2014

Abstract

Hallux rigidus describes the osteoarthritis of the first metatarsophalangeal joint. It was first mentioned in 1887. Since then a multitude of terms have been introduced referring to the same disease. The main complaints are pain especially during movement and a limited range of motion. Radiographically the typical signs of osteoarthritis can be observed starting at the dorsal portion of the joint. Numerous classifications make the comparison of the different studies difficult. If non-operative treatment fails to resolve the symptoms operative treatment is indicated. The most studied procedure with reproducible results is the arthrodesis. Nevertheless, many patients refuse this treatment option, favouring a procedure preserving motion. Different motion preserving and joint sacrificing operations such as arthroplasty are available. In this review we focus on motion and joint preserving procedures. Numer-

ous joint preserving osteotomies have been described. Most of them try to relocate the viable plantar cartilage more dorsally, to decompress the joint and to increase dorsiflexion of the first metatarsal bone. Multiple studies are available investigating these procedures. Most of them suffer from low quality, short follow up and small patient numbers. Consequently the grade of recommendation is low. Nonetheless, joint preserving procedures are appealing because if they fail to relieve the symptoms an arthrodesis or arthroplasty can still be performed thereafter.

© 2014 Baishideng Publishing Group Co., Limited. All rights reserved.

Key words: Hallux rigidus; Osteoarthritis; First metatarsophalangeal joint; Joint preserving; Operative treatment; Osteotomy

Core tip: If nonoperative treatment fails to relieve the symptoms of hallux rigidus surgery is indicated. The procedure with the most evidence for success is the arthrodesis of the first metatarsophalangeal joint. Nevertheless, many patients prefer treatment options which preserve the joint motion. The evidence for different arthroplastic procedures is of low quality. Furthermore, in case the procedure fails to relieve the symptoms to perform an arthrodesis after resection of the joint is much more difficult and may require bone graft. Consequently, joint and motion preserving osteotomies are of great interest for treatment of hallux rigidus. We here provide a review of the different joint and motion preserving alternatives for treating hallux rigidus and the studies available investigating these procedures.

Polzer H, Polzer S, Brumann M, Mutschler W, Regauer M. Hallux rigidus: Joint preserving alternatives to arthrodesis - a review of the literature. *World J Orthop* 2014; 5(1): 6-13 Available from: URL: <http://www.wjgnet.com/2218-5836/full/v5/i1/6.htm> DOI: <http://dx.doi.org/10.5312/wjo.v5.i1.6>

INTRODUCTION

The term “hallux rigidus” refers to the osteoarthritis of the metatarsophalangeal joint (MTPJ) of the first toe. This disease was first reported in 1887 by Davies-Colley^[1]. He suggested the name “hallux flexus”. Shortly thereafter Cotterill was the first to introduce the term “hallux rigidus”^[2]. Since then multiple names have been suggested, such as metatarsus primus elevatus, dorsal bunion, hallux dolorosus, or hallux malleus, to describe the same diagnosis. It is one of the most common problems of the great toe^[3].

ETIOLOGY

Hallux rigidus is a common form of osteoarthritis in the foot^[4]. Radiographic signs for the disease can be recognized in 10% of people aged 20-34 years and 44% of people over the age of 80 years^[5]. The exact cause for hallux rigidus is controversial. Coughlin *et al.*^[6] (2003) demonstrated that 80% of all patients suffering from bilateral hallux rigidus have a family history. Furthermore, in a long term study they could depict that most patients develop a bilateral hallux rigidus over time^[6]. Some authors blame poor footwear^[1], a tight achilles tendon^[7] or believe in a spontaneous onset^[8]. Another popular concept is that an elevated first ray, the so called metatarsus primus elevatus, leads to hallux rigidus. While many authors are in favour of this theory^[9-13], there are multiple surgeons opposing it^[14-16]. Coughlin *et al.*^[6] even propose that the metatarsus primus elevatus might be a secondary change due to hallux rigidus. Taken together, the exact cause leading to hallux rigidus remains controversial. Nevertheless, it is known that females show a higher incidence^[10,14,17,18] and that it mainly occurs after the age of 40 years^[6]. The most common cause for unilateral hallux rigidus is believed to be traumatic, either by isolated injury or repetitive microtraumata^[14,19,20]. These can cause chondral injury and lead to progressive arthritic changes. However, most of these concepts are theoretical and lack scientific evidence.

CLINICAL FINDINGS

Hallux rigidus is characterised by arthralgia, which is usually worsened by walking. With time the joint enlarges and the symptoms become more pronounced with pain at the dorsal bony prominence of the first MTPJ^[6] and decreased range of motion, especially dorsiflexion. In this process the destruction of the cartilage commonly starts at the dorsal portion of the metatarsal head^[21] and the bony prominence might impinge against the proximal phalanx (Figure 1). Physical examination usually shows a painful, tender and swollen first MTPJ with limited motion and pain usually when dorsiflexed.

RADIOGRAPHIC FINDINGS

Radiographic examination should include weight-bearing

anteroposterior and lateral radiographs^[22]. The typical radiographic findings are asymmetric joint narrowing and a flattened metatarsal head (Figure 1). With advancement of the disease more of the joint surface is involved and subchondral cysts, sclerosis and bony proliferation at the joint margins occur and the joint narrowing progresses^[22,23].

GRADING

Multiple different grading system for hallux rigidus have been introduced differentiating between two and five different grades^[11,12,21,22,24-30]. A classification system should aid the decision on treatment and allow a meaningful comparison of different treatment strategies. Furthermore, in order to compare the results of different studies and procedures a consistent classification is crucial. Beeson *et al.*^[31] (2008) performed a systematic review of the literature to critically evaluate the different classification systems for hallux rigidus. The authors criticize, that none of the classification systems has been tested in regard to reliability and validity. Taking this shortcoming into account they consider the classification system by Coughlin *et al.*^[22] to be the closest to a “gold standard”. These authors base their classification on subjective and objective clinical and radiographic findings (Table 1).

NONOPERATIVE TREATMENT

Nonoperative treatment of hallux rigidus should be applied in accordance to the degree of symptoms. Anti-inflammatory medications and strapping of the toe might be sufficient. Furthermore, shoe modification or the use of rigid shoe inserts and modification of activities might be beneficial^[22,32]. Little evidence is available for injection of sodium hyaluronate, but it seems to be beneficial only in the early state^[33,34]. Zammit *et al.*^[35] performed a systematic review and identified only one high class randomised controlled trial evaluating conservative interventions for hallux rigidus. Shamus *et al.*^[36] compared physical therapy alone to physical therapy combined with sesamoid mobilization, flexor hallucis strengthening exercises, and gait training. The authors concluded that combined multifaceted physical therapy reduces pain and restores function more sufficiently. When nonoperative treatment fails to provide relief, surgery should be performed.

JOINT DESTRUCTIVE SURGICAL TECHNIQUES

Arthrodesis

The best evidence available is in support of arthrodesis for the first MTPJ. When compared to total arthroplasty^[37], hemiarthroplasty^[38], resection arthroplasty^[39], interpositional arthroplasty or cheilectomy^[40,41], arthrodesis yielded better reduction of pain, better functional satisfaction, shorter hospital stays, lower revision rates and faster return to normal activity^[42]. Nevertheless, joint and motion preserving operations are appealing, because

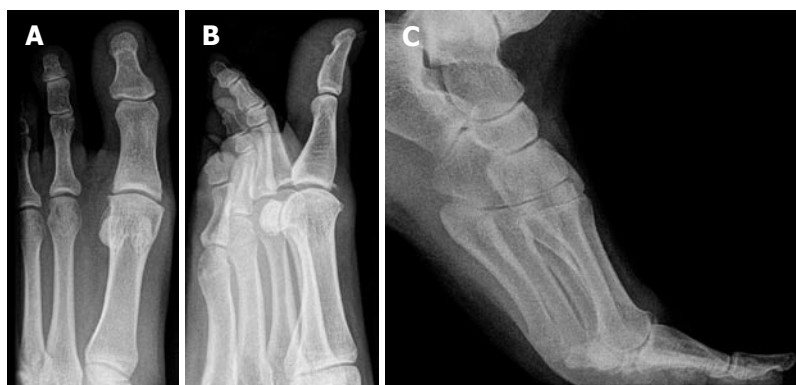

Figure 1 Radiographic images of a hallux rigidus grade 2. A: Dorso-plantar view; B: Oblique view; C: Stress radiographs in dorsiflexion revealing bony impingement.

Table 1 Clinical and radiographic grading for hallux rigidus

Grade	Dorsiflexion	Radiographic findings	Clinical findings
0	40°-60° and/or 10%-20% loss compared with normal side	Normal	No pain; only stiffness and loss of motion
1	30°-40° and/or 20%-50% loss compared with normal side	Dorsal osteophyte (main finding), minimal joint space narrowing, periarticular sclerosis, flattening of metatarsal head	Mild or occasional pain and stiffness, pain at extremes of dorsiflexion and/or plantar flexion
2	10°-30° and/or 50%-75% loss compared with normal side	Dorsal, lateral, and possibly medial osteophytes (flattened metatarsal head) < 1/4 of dorsal joint space involved (lateral radiograph), mild to moderate joint-space narrowing and sclerosis, sesamoids not involved	Moderate to severe pain and stiffness that may be constant; pain just before maximum dorsiflexion and maximum plantar flexion
3	≤ 10° and/or 75%-100% loss compared with normal side. Notable loss of plantar flexion (often ≤ 10°)	Same as in Grade 2 but with substantial narrowing, possibly periarticular cysts, > 1/4 of dorsal joint space involved (lateral radiograph), sesamoids enlarged and/or cystic and/or irregular	Nearly constant pain and substantial stiffness at extremes of range of motion but not at mid-range
4	Same as in Grade 3	Same as in Grade 3	Same as in Grade 3 but definite pain at mid-range of passive motion

if they fail to relieve the symptoms, an arthrodesis can still be performed.

Arthroplasty

Different methods of arthroplasty are available. The studies comparing arthroplasty using nontissue implants compared various different implants^[37,43-45] and produced conflicting results^[40]. Arthroplasty by resection also seems to be effective for treatment of hallux rigidus^[39,41,46], although it could not be demonstrated that it is superior to other techniques. The same applies to the interpositional arthroplasty^[40,46-48].

Cheilectomy

This procedure was introduced in 1979 by Mann *et al*^[15]. In addition to the osteophytes of the base of the proximal phalanx 25%-30% of the dorsal metatarsal head are removed (Figure 2A). Consequently, the procedure must be classified as a partially joint sacrificing technique. Too aggressive resection may lead to a MTPJ subluxation. Furthermore, arthrodesis or arthroplasty are more difficult thereafter. Only retrospective trials are available comparing cheilectomy to other surgical interventions^[40,41,44,49]. There is no consistent evidence that cheilectomy is superior to other operative interventions^[42], while it was used mainly in low grades of hallux rigidus.

JOINT PRESERVING SURGICAL TECHNIQUES

Proximal phalanx osteotomy (Moberg)

One of the main clinical findings in hallux rigidus is the painful limited range of motion, especially of dorsiflexion. Therefore, the concept of the proximal phalanx osteotomy is to reset the arc of motion by placing the toe into a more extended position (Figure 2B). This should better accommodate the need for dorsiflexion^[50]. Bonney *et al*^[51] were the first to describe this concept in 1952 and called it “greenstick extension osteotomy of the proximal phalanx”. Kessel *et al*^[52] and Moberg^[3] were the first to perform retrospective case series reporting promising results and suggesting “that further testing of this method should be worthwhile”. The only prospective trial investigating proximal phalanx osteotomy was performed by Kilmartin^[53]. They compared the proximal phalanx osteotomy (49 joints) to different metatarsal decompression osteotomies (59 joints). Unfortunately the sample size for each procedure in the metatarsal decompression osteotomy group was decreased by mixing the proximal plantar displacement osteotomy, the modified Reverdin Green osteotomy and the shortening scarf osteotomy. In both groups a significant increase of the AOFAS score could be noted. A higher satisfaction rate and a lower

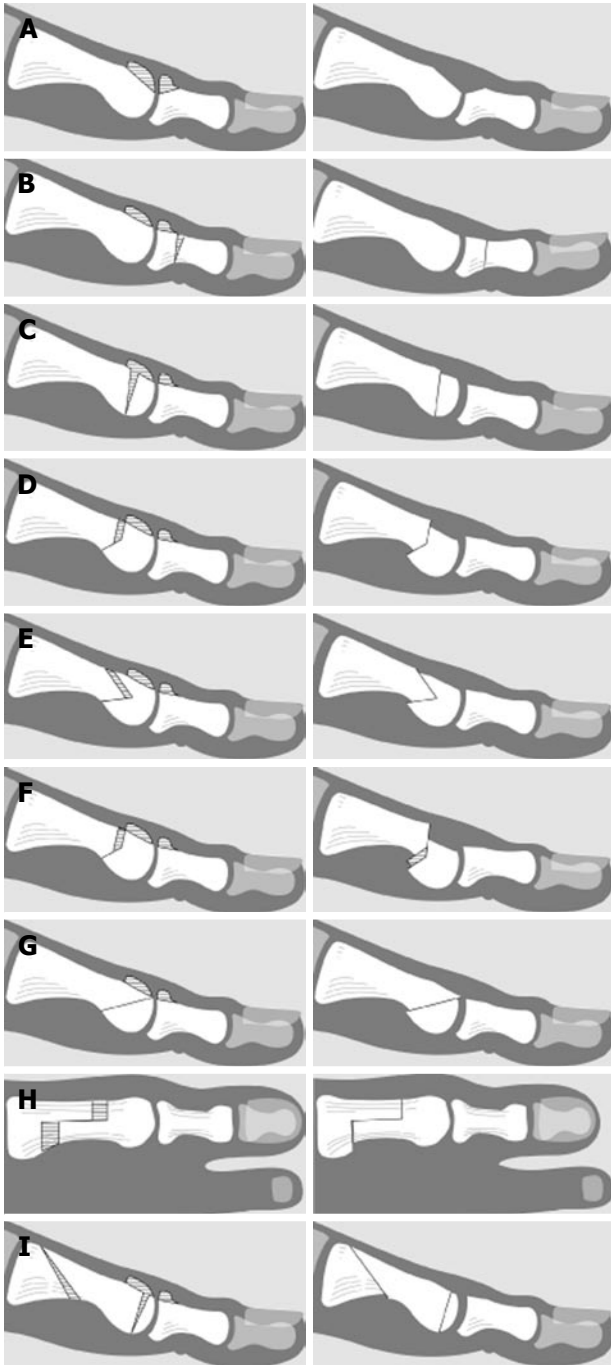


Figure 2 Diagrammatic presentations. A: A Cheilectomy; B: A proximal phalanx osteotomy (Moberg); C: A dorsal closing wedge osteotomy (Watermann); D: A Watermann Green procedure; E: A Youngswick procedure; F: A Reverdin Green osteotomy; G: A distal oblique sliding osteotomy; H: The Sagittal Z osteotomy; I: A Drago procedure.

complication rate were observed for the proximal phalangeal osteotomy although without significant differences. In a retrospective long term follow up study Citron *et al.*^[54] found complete pain relief shortly after the operation compared with 50% pain relief after an average follow up of 22 years (10 joints). Blyth *et al.*^[55] retrospectively analysed 18 osteotomies with a follow up period of four years and found significant improvement for pain, footwear difficulties and range of motion. Fourteen of

the eighteen patients evaluated the result of the surgery as good or excellent. Southgate *et al.*^[56] retrospectively compared the proximal phalanx osteotomy (10 joints) to arthrodesis (20 joints) with an average follow up of 12 years. Without performing statistical analysis they found comparable results for both procedures, with less complications but greater changes of the foot pressure for the osteotomies. Mesa-Ramos *et al.*^[57] evaluated 26 minimal invasive procedures including a proximal phalanx osteotomy in combination with a capsular release and resection of bony spurs. The authors also found a good pain reduction with an increasing AOFAS score and a high patient satisfaction. Furthermore, few low quality retrospective case series investigated either only the proximal phalanx osteotomy^[55] or the combination with cheilectomy^[58]. Due to the low quality the only conclusion from these trials is, that the procedure is safe and that it seems to provide relief of symptoms.

Taken together, the evidence available is not good enough to draw a definitive conclusion, whether the proximal phalanx osteotomy is superior to other operative techniques. Nevertheless, the procedure seems to be safe and to reduce pain.

Dorsal closing wedge osteotomy (Watermann)

Watermann was the first to report a dorsal closing wedge trapezoidal osteotomy of the distal metatarsal (Figure 2C)^[59]. It was designed to relocate the viable plantar cartilage to a more dorsal location, thereby allowing more dorsiflexion of the hallux^[60]. It further causes a decompression of the joint^[61]. Cavolo *et al.*^[61] reported two cases and found an increased range of motion and a high patient satisfaction. To our knowledge there are no further studies available evaluating this technique. From our point of view the major disadvantage is that the osteotomy is relatively unstable due to the perpendicular orientation of the osteotomy in relation to the metatarsal shaft and the resulting difficult fixation^[60]. Furthermore, some authors state that this procedure is contraindicated in metatarsus primus elevates, as it could increase the symptoms^[60]. From the little evidence available, no recommendation for this procedure can be made.

Watermann Green

The name Watermann Green is misleading as the procedure originally was not designed to rotate the articular cartilage compared to the original Watermann procedure. The procedure describes a 2-arm osteotomy. The dorsal arm consists of two incomplete osteotomies 0.5 cm proximal to the articular cartilage of the first metatarsal head in order to shorten the first metatarsal. If these two cuts form a trapezoid, the proximal articular set angle can be changed. The plantar osteotomy of was originally angled 135 degrees to the dorsal arm and causes a plantar transposition (Figure 2D). This angle can be modified thereby changing the ratio of the first metatarsal shortening to the plantar transposition of the capital fragment. It is often combined with a cheilectomy. It is difficult to

clearly delineate this procedure from the Youngswick osteotomy as the angle between the two limbs can vary depending on whether the shortening or the plantar translation is more important^[62] for both procedures resulting in comparable osteotomies.

Dickerson *et al.*^[63] also retrospectively analysed 28 Watermann Green procedures with an average follow up of four years. Ninety-four percent of all patients reported an extensive relief of pain and 75% experienced a subjective increase of the range of motion. Roukis *et al.*^[43] prospectively compared the periarticular osteotomy either according to Watermann Green or Youngswick (16 patients) to a resurfacing endoprosthesis (9 patients). The authors did not find significant differences for subjective and objective measures. The only difference found was a reduced metatarsal protrusion distance, but due to the limited follow up of one year, the importance of this finding could not be delineated. Furthermore, the authors do not state how many Watermann Green and how many Youngswick procedures were performed and do not evaluate the results for the two procedures independently. Consequently, the conclusions drawn are limited.

Youngswick

This procedure was introduced by Youngswick^[64] in 1982 as a modification of the Chevron osteotomy. First a V-shaped osteotomy is performed with the apex directed distally and two diagonal arms are directed dorsal proximal and plantar proximal at a 60 degree angle. Then, a second osteotomy is performed parallel to the dorsal limb of the first osteotomy (Figure 2E). This results in a shortening of the first metatarsal thereby leading to a decompression of the first MTPJ. Further it tries to plantar translate the first metatarsal head which may decrease metatarsalgia and dorsal impingement.

Giannini *et al.*^[65] retrospectively evaluated eight patients with less severe hallux rigidus and found an improvement of both the AOFAS score as well as joint motion. Unfortunately no statistical analysis was performed and the results of this procedure were not clearly confined from the results of other osteotomies. Oloff *et al.*^[66] retrospectively evaluated the outcome of the Youngswick procedure in 28 feet in late stage hallux rigidus. The operation led to a significant improvement of pain, function, range of motion in pain, the AOFAS score and significant less shoe restrictions. The authors reported an overall patient satisfaction of more than 85%, with the patients' chief complaint alleviated in more than 75%. Yet, the authors included combinations of the osteotomy with or without cheilectomy and/or chondroplasty and do not specify the number of these adjunct procedures. This makes the interpretation of these results difficult. Roukis *et al.*^[43] conducted a prospective trial comparing the Youngswick as well as the Watermann Green osteotomy to a resurfacing endoprosthesis. The authors did not find significant differences for the AOFAS scores between the two study groups, while the AOFAS score in both groups significantly increased from pre- to postoperatively. Main limitations of the study were, that it was not identified how

many Youngswick and Watermann Green osteotomies were performed. Furthermore, they did not provide a detailed statistical analysis and only performed a follow up to twelve months. They concluded that further long-term studies are needed in order to draw a definitive conclusion. Bryant *et al.*^[67] demonstrated that the Youngswick procedure changes the plantar peak pressure distribution in the forefoot. Yet, the importance of this finding is still unclear.

Reverdin Green

The Reverdin Green osteotomy is a modification of the Youngswick procedure. After performing the V-shaped osteotomy a second osteotomy is performed parallel to the dorsal limb of the V-shaped osteotomy and the excised bone block is implanted in the plantar limb of the osteotomy to further translate the metatarsal head plantarwards (Figure 2F). The only prospective trial investigating the Reverdin Green osteotomy was performed by Kilmartin^[53]. They included three different metatarsal decompression osteotomies, namely the Reverdin Green, the plantar proximal displacement and the shortening Scarf osteotomy and compared them to the proximal phalanx osteotomy. The authors performed 30 Reverdin Green osteotomies, but due to complications they instead continued with a plantar proximal displacement osteotomy. Unfortunately the authors do not state the nature of the complications. Furthermore, they do not report the results of the different osteotomies. The authors state that the decompression osteotomies resulted in a lower patient satisfaction rate and a higher complication rate when compared to the phalangeal osteotomy and conclude that neither of the procedures could be considered definitive for hallux rigidus.

We believe that the results of the Reverdin Green procedure cannot be judged due to the low quality of the data available. Nevertheless, the high rate of reported but not further specified complications must be noted.

Distal oblique sliding osteotomy

This osteotomy is carried out in a distal to proximal direction beginning slightly proximal of the articular surface in an angle of 35°-45° oblique to the sagittal plane. The capital fragment is then displaced proximally and thereby leading to plantar displacement (Figure 2G). Consequently this procedure leads to both a decompression of the first MTPJ and a plantar displacement of the first metatarsal head. Lundeen *et al.*^[13] initially introduced this concept for treatment of hallux valgus associated with hallux limitus, but it has been adopted for treatment of hallux rigidus only.

Giannini *et al.*^[65] retrospectively analysed ten joints with low grade hallux rigidus treated by distal oblique sliding osteotomy. The AOFAS score as well as joint motion could be improved. As stated above no statistical analysis was performed and the results of this procedure were not clearly confined from the results of the Youngswick osteotomy. Ronconi *et al.*^[68] retrospectively evaluated 30 osteotomies with a mean follow up of 21

mo. They demonstrated an increased range of motion of the first MTPJ and a high patient satisfaction rate, while the number of patients with excessive pressure on the second and third metatarsal head increased and the forefoot supination angle decreased postoperatively. Gonzalez *et al*^[69] performed a retrospective study of 25 joints. They included less and more severe grades (II-III according to Drago *et al*^[11]). The authors report a subjective satisfaction rate of 96% with a return to normal activity within two months for 80% of all patients and a significant increase of dorsiflexion of 41.2° in average, while 28% reported subjective limitation of joint motion. The authors do not comment on metatarsalgia of the lesser toes. Further limiting is the short follow up of twelve months only, consequently it cannot be evaluated whether this gain in motion can be maintained over time. Malerba *et al*^[70] retrospectively analysed 20 joints treated with a distal oblique sliding osteotomy with an average follow-up of 11.1 years. They found a significant increase of the AOFAS score as well as in the range of motion and concluded that the procedure is safe and reliable and provides a high patient satisfaction. Kilmartin^[53] operated 15 patients with grade II hallux rigidus. The authors state that metatarsal decompression is associated with a high risk of transfer metatarsalgia, but as pointed out above they used three different techniques and do not state the results for each procedure individually. None of these authors observed severe complications such as head necrosis or non-union of the osteotomy.

Sagittal Z osteotomy

The sagittal Z osteotomy also aims at shortening and thereby decompressing the first MTPJ (Figure 2H). Further it allows plantarflexion of the MTPJ. The greatest advantages of this procedure are the high cross-sectional area for bone healing, the great shortening potential and the ability to be fixated with multiple screws in combination with a low risk for avascular necrosis^[60]. This procedure was always performed in combination with a cheilectomy. This combinatory approach makes it difficult to determine the outcomes of the osteotomy and cheilectomy. The evidence for this procedure is low. Kissel *et al*^[71] evaluated the results of the sagittal Z osteotomy in combination with cheilectomy and chondroplasty and found good patient satisfaction rate without performing statistical analysis. Viegas^[72] performed 13 procedures and found only good and excellent results. Again the authors did not acquire objective measurements and consequently they could not perform statistical analysis.

Drago

Drago *et al*^[11] presented a double osteotomy consisting of a Watermann procedure at the distal end of the first MT and a proximal plantarflexing osteotomy. The idea was to perform a proximal osteotomy in order to allow more plantarflexion compared to the distal osteotomy. The authors hypothesised, that this could lead to a dorsal jamming of the first MTPJ. In order to prevent this effect and to rotate the articular surface dorsally, they combined

this osteotomy with a Watermann procedure (Figure 2I). To our knowledge no study has yet evaluated the results of this procedure.

Modifications

Furthermore, there are various modifications of the previously depicted osteotomies. All studies evaluating such procedures were retrospectively performed without a control group. Yet, all authors claim good results for their procedures.

Derner *et al*^[73] presented a modification of the Youngswick procedure. Their first cut is straight in contrast to the V-shaped osteotomy by Youngswick. The second osteotomy is performed parallel to the dorsal two thirds of the first osteotomy. The authors report an increase of the range of motion of 38° with an excellent patient satisfaction of 85%.

Selner *et al*^[74] performed a retrospective analysis of a tricorrectional osteotomy (18 joints) with an average follow up of 32 mo. It is basically a modified Youngswick procedure but it allows to change the orientation of the first MTPJ.

Kilmartin^[53] performed a shortening Scarf osteotomy in 14 patients. They state that the increase in range of motion is limited but a high number of patients suffered from transfer-metatarsalgia without specifying these results. As depicted above this study suffers multiple shortcomings.

CONCLUSION

The evidence currently available investigating the different procedures is poor. Especially the clinical heterogeneity and the low number of prospective trials are the reason why it is not possible to compare outcomes for patients undergoing the different surgical procedures. Consequently the grade of recommendation for each procedure is low and the choice of the procedure still is an individual decision of the treating surgeon until better prospective trials are available. Nevertheless, joint preserving operations are appealing, because if they fail to relieve the symptoms, joint sacrificing operations can still be performed.

ACKNOWLEDGMENTS

We thank Mrs Hella Thun for preparation of the figures.

REFERENCES

- 1 Davies-Colley N. Contraction of the metatarsophalangeal joint of the great toe. *Br Med J* 1887; 1: 728
- 2 Cotterill JM. Stiffness of the Great Toe in Adolescents. *Br Med J* 1887; 1: 1158 [PMID: 20751923 DOI: 10.1136/bmj.1.1378.1158]
- 3 Moberg E. A Simple Operation for Hallux Rigidus. *Clin Orthop* 1979; (142): 55-56
- 4 Weinfeld SB, Schon LC. Hallux metatarsophalangeal arthritis. *Clin Orthop Relat Res* 1998; (349): 9-19 [PMID: 9584362 DOI: 10.1097/00003086-199804000-00003]
- 5 van Saase JL, van Romunde LK, Cats A, Vandenbroucke JP, Valkenburg HA. Epidemiology of osteoarthritis: Zoetermeer survey. Comparison of radiological osteoarthritis in a Dutch

- population with that in 10 other populations. *Ann Rheum Dis* 1989; **48**: 271-280 [PMID: 2712610 DOI: 10.1136/ard.48.4.271]
- 6 **Coughlin MJ**, Shurnas PS. Hallux rigidus: demographics, etiology, and radiographic assessment. *Foot Ankle Int* 2003; **24**: 731-743 [PMID: 14587987 DOI: 10.1177/107110070302401002]
 - 7 **Bingold AC**, Collins DH. Hallux rigidus. *J Bone Joint Surg Br* 1950; **32-B**: 214-222 [PMID: 15422020]
 - 8 **Jack EA**. The Aetiology of Hallux Rigidus. *Br J Surg* 1940; **27**: 492-497 [DOI: 10.1002/bjs.18002710710]
 - 9 **Camasta CA**. Hallux limitus and hallux rigidus. Clinical examination, radiographic findings, and natural history. *Clin Podiatr Med Surg* 1996; **13**: 423-448 [PMID: 8829034]
 - 10 **Cosentino GL**. The Cosentino modification for tendon interpositional arthroplasty. *J Foot Ankle Surg* 1995; **34**: 501-508 [PMID: 8590887]
 - 11 **Drago JJ**, Oloff L, Jacobs AM. A comprehensive review of hallux limitus. *J Foot Surg* 1984; **23**: 213-220 [PMID: 6376607]
 - 12 **Geldwert JJ**, Rock GD, McGrath MP, Mancuso JE. Cheilectomy: still a useful technique for grade I and grade II hallux limitus/rigidus. *J Foot Surg* 1992; **31**: 154-159 [PMID: 1645002]
 - 13 **Lundeen RO**, Rose JM. Sliding oblique osteotomy for the treatment of hallux abducto valgus associated with functional hallux limitus. *J Foot Ankle Surg* 2000; **39**: 161-167 [PMID: 10862387 DOI: 10.1016/S1067-2516(00)80017-4]
 - 14 **Bryant A**, Tinley P, Singer K. A comparison of radiographic measurements in normal, hallux valgus, and hallux limitus feet. *J Foot Ankle Surg* 2000; **39**: 39-43 [PMID: 10658949 DOI: 10.1016/S1067-2516(00)80062-9]
 - 15 **Mann RA**, Coughlin MJ, DuVries HL. Hallux rigidus: A review of the literature and a method of treatment. *Clin Orthop Relat Res* 1979; (**142**): 57-63 [PMID: 498649]
 - 16 **Horton GA**, Park YW, Myerson MS. Role of metatarsus primus elevatus in the pathogenesis of hallux rigidus. *Foot Ankle Int* 1999; **20**: 777-780 [PMID: 10609705 DOI: 10.1177/107110079902001204]
 - 17 **Chang TJ**. Stepwise approach to hallux limitus. A surgical perspective. *Clin Podiatr Med Surg* 1996; **13**: 449-459 [PMID: 8829035]
 - 18 **Beeson P**, Phillips C, Corr S, Ribbans WJ. Cross-sectional study to evaluate radiological parameters in hallux rigidus. *Foot (Edinb)* 2009; **19**: 7-21 [PMID: 20307444 DOI: 10.1016/j.foot.2008.07.002]
 - 19 **Frimenko RE**, Lievers W, Coughlin MJ, Anderson RB, Crandall JR, Kent RW. Etiology and biomechanics of first metatarsophalangeal joint sprains (turf toe) in athletes. *Crit Rev Biomed Eng* 2012; **40**: 43-61 [PMID: 22428798]
 - 20 **Frey C**, Andersen GD, Feder KS. Plantarflexion injury to the metatarsophalangeal joint ("sand toe"). *Foot Ankle Int* 1996; **17**: 576-581 [PMID: 8886789 DOI: 10.1177/107110079601700914]
 - 21 **Hattrup SJ**, Johnson KA. Subjective results of hallux rigidus following treatment with cheilectomy. *Clin Orthop Relat Res* 1988; (**226**): 182-191 [PMID: 3335093]
 - 22 **Coughlin MJ**, Shurnas PS. Hallux rigidus. Grading and long-term results of operative treatment. *J Bone Joint Surg Am* 2003; **85-A**: 2072-2088 [PMID: 14630834]
 - 23 **Shurnas PS**. Hallux rigidus: etiology, biomechanics, and nonoperative treatment. *Foot Ankle Clin* 2009; **14**: 1-8 [PMID: 19232987 DOI: 10.1016/j.fcl.2008.11.001]
 - 24 **Nilsonne H**. Hallux rigidus and its treatment. *Acta Orthop Scand* 1930; **1**: 295-303
 - 25 **Barca F**. Tendon arthroplasty of the first metatarsophalangeal joint in hallux rigidus: preliminary communication. *Foot Ankle Int* 1997; **18**: 222-228 [PMID: 9127112 DOI: 10.1177/107110079701800407]
 - 26 **Easley ME**, Davis WH, Anderson RB. Intermediate to long-term follow-up of medial-approach dorsal cheilectomy for hallux rigidus. *Foot Ankle Int* 1999; **20**: 147-152 [PMID: 10195291 DOI: 10.1177/107110079902000302]
 - 27 **Hanft JR**, Mason ET, Landsman AS, Kashuk KB. A new radiographic classification for hallux limitus. *J Foot Ankle Surg* 1993; **32**: 397-404 [PMID: 8251995]
 - 28 **Karasick D**, Schweitzer ME. Disorders of the hallux sesamoid complex: MR features. *Skeletal Radiol* 1998; **27**: 411-418 [PMID: 9765133]
 - 29 **Karasick D**, Wapner KL. Hallux rigidus deformity: radiologic assessment. *AJR Am J Roentgenol* 1991; **157**: 1029-1033 [PMID: 1927789 DOI: 10.2214/ajr.157.5.1927789]
 - 30 **Karasick D**, Wapner KL. Hallux valgus deformity: preoperative radiologic assessment. *AJR Am J Roentgenol* 1990; **155**: 119-123 [PMID: 2112832 DOI: 10.2214/ajr.155.1.2112832]
 - 31 **Beeson P**, Phillips C, Corr S, Ribbans W. Classification systems for hallux rigidus: a review of the literature. *Foot Ankle Int* 2008; **29**: 407-414 [PMID: 18442456 DOI: 10.3113/FAI.2008.0407]
 - 32 **Grady JF**, Axe TM, Zager EJ, Sheldon LA. A retrospective analysis of 772 patients with hallux limitus. *J Am Podiatr Med Assoc* 2002; **92**: 102-108 [PMID: 11847262]
 - 33 **Pons M**, Alvarez F, Solana J, Viladot R, Varela L. Sodium hyaluronate in the treatment of hallux rigidus. A single-blind, randomized study. *Foot Ankle Int* 2007; **28**: 38-42 [PMID: 17257536 DOI: 10.3113/FAI.2007.0007]
 - 34 **Solan MC**, Calder JD, Bendall SP. Manipulation and injection for hallux rigidus. Is it worthwhile? *J Bone Joint Surg Br* 2001; **83**: 706-708 [PMID: 11476310 DOI: 10.1302/0301-620X.83B5.11425]
 - 35 **Zammit GV**, Menz HB, Munteanu SE, Landorf KB, Gilheany MF. Interventions for treating osteoarthritis of the big toe joint. *Cochrane Database Syst Rev* 2010; (**9**): CD007809 [PMID: 20824867 DOI: 10.1002/14651858.CD007809.pub2]
 - 36 **Shamus J**, Shamus E, Gugel RN, Brucker BS, Skaruppa C. The effect of sesamoid mobilization, flexor hallucis strengthening, and gait training on reducing pain and restoring function in individuals with hallux limitus: a clinical trial. *J Orthop Sports Phys Ther* 2004; **34**: 368-376 [PMID: 15296364]
 - 37 **Gibson JN**, Thomson CE. Arthrodesis or total replacement arthroplasty for hallux rigidus: a randomized controlled trial. *Foot Ankle Int* 2005; **26**: 680-690 [PMID: 16174497]
 - 38 **Raikin SM**, Ahmad J, Pour AE, Abidi N. Comparison of arthrodesis and metallic hemiarthroplasty of the hallux metatarsophalangeal joint. *J Bone Joint Surg Am* 2007; **89**: 1979-1985 [PMID: 17768195 DOI: 10.2106/JBJS.F.01385]
 - 39 **Crymble BT**. The results of arthrodesis of great toe; with special reference to hallux rigidus. *Lancet* 1956; **271**: 1134-1136 [PMID: 13377692]
 - 40 **Keiserman LS**, Sammarco VJ, Sammarco GJ. Surgical treatment of the hallux rigidus. *Foot Ankle Clin* 2005; **10**: 75-96 [PMID: 15831259 DOI: 10.1016/j.fcl.2004.09.005]
 - 41 **Beertema W**, Draijer WF, van Os JJ, Pilot P. A retrospective analysis of surgical treatment in patients with symptomatic hallux rigidus: long-term follow-up. *J Foot Ankle Surg* 2006; **45**: 244-251 [PMID: 16818152 DOI: 10.1053/j.jfas.2006.04.006]
 - 42 **McNeil DS**, Baumhauer JF, Glazebrook MA. Evidence-based analysis of the efficacy for operative treatment of hallux rigidus. *Foot Ankle Int* 2013; **34**: 15-32 [PMID: 23386758 DOI: 10.1177/107110071246022034/1/15]
 - 43 **Roukis TS**, Townley CO. BIOPRO resurfacing endoprosthesis versus periarticular osteotomy for hallux rigidus: short-term follow-up and analysis. *J Foot Ankle Surg* 2003; **42**: 350-358 [PMID: 14688777 DOI: 10.1053/j.jfas.2003.09.006]
 - 44 **Pontell D**, Gudas CJ. Retrospective analysis of surgical treatment of hallux rigidus/limitus: clinical and radiographic follow-up of hinged, silastic implant arthroplasty and cheilectomy. *J Foot Surg* 2003; **27**: 503-510 [PMID: 3243957]
 - 45 **Raikin SM**, Ahmad J. Comparison of arthrodesis and metallic hemiarthroplasty of the hallux metatarsophalangeal joint. Surgical technique. *J Bone Joint Surg Am* 2008; **90** Suppl 2 Pt 2: 171-180 [PMID: 18829931 DOI: 10.2106/JBJS.H.00368]
 - 46 **Schenk S**, Meizer R, Kramer R, Aigner N, Landsiedl F, Steinboeck G. Resection arthroplasty with and without capsular interposition for treatment of severe hallux rigidus. *Int Or-*

- thop* 2009; **33**: 145-150 [PMID: 17929015 DOI: 10.1007/s00264-007-0457-z]
- 47 **Mackey RB**, Thomson AB, Kwon O, Mueller MJ, Johnson JE. The modified oblique keller capsular interpositional arthroplasty for hallux rigidus. *J Bone Joint Surg Am* 2010; **92**: 1938-1946 [PMID: 20720136 DOI: 10.2106/JBJS.I.00412]
- 48 **Lau JT**, Daniels TR. Outcomes following cheilectomy and interpositional arthroplasty in hallux rigidus. *Foot Ankle Int* 2001; **22**: 462-470 [PMID: 11475452 DOI: 10.1177/107110070102200602]
- 49 **Coughlin MJ**, Shurnas PS. Hallux rigidus. *J Bone Joint Surg Am* 2004; **86-A** Suppl 1: 119-130 [PMID: 15466753]
- 50 **Seibert NR**, Kadakia AR. Surgical management of hallux rigidus: cheilectomy and osteotomy (phalanx and metatarsal). *Foot Ankle Clin* 2009; **14**: 9-22 [PMID: 19232988 DOI: 10.1016/j.fcl.2008.11.002]
- 51 **Bonney G**, Macnab I. Hallux valgus and hallux rigidus; a critical survey of operative results. *J Bone Joint Surg Br* 1952; **34-B**: 366-385 [PMID: 12999918]
- 52 **Kessel L**, Bonney G. Hallux rigidus in the adolescent. *J Bone Joint Surg Br* 1958; **40-B**: 669-673 [PMID: 13610981]
- 53 **Kilmartin TE**. Phalangeal osteotomy versus first metatarsal decompression osteotomy for the surgical treatment of hallux rigidus: a prospective study of age-matched and condition-matched patients. *J Foot Ankle Surg* 2005; **44**: 2-12 [PMID: 15704077 DOI: 10.1053/j.jfas.2004.11.013]
- 54 **Citron N**, Neil M. Dorsal wedge osteotomy of the proximal phalanx for hallux rigidus. Long-term results. *J Bone Joint Surg Br* 1987; **69**: 835-837 [PMID: 3680354]
- 55 **Blyth MJ**, Mackay DC, Kinninmonth AW. Dorsal wedge osteotomy in the treatment of hallux rigidus. *J Foot Ankle Surg* 1998; **37**: 8-10 [PMID: 9470110 DOI: 10.1016/S1067-2516(98)80004-5]
- 56 **Southgate JJ**, Urry SR. Hallux rigidus: the long-term results of dorsal wedge osteotomy and arthrodesis in adults. *J Foot Ankle Surg* 1997; **36**: 136-40; discussion 161 [PMID: 9127218 DOI: 10.1016/S1067-2516(97)80060-9]
- 57 **Mesa-Ramos M**, Mesa-Ramos F, Carpintero P. Evaluation of the treatment of hallux rigidus by percutaneous surgery. *Acta Orthop Belg* 2008; **74**: 222-226 [PMID: 18564480]
- 58 **Thomas PJ**, Smith RW. Proximal phalanx osteotomy for the surgical treatment of hallux rigidus. *Foot Ankle Int* 1999; **20**: 3-12 [PMID: 9921765 DOI: 10.1177/107110079902000102]
- 59 **Watermann H**. Die Arthritis Deformans des Grozehen-Gruengelenkes als Selbstndiges Krankheitsbild. *Z Orthop Chir* 1927; **48**: 346-355
- 60 **Freeman BL**, Hardy MA. Multiplanar phalangeal and metatarsal osteotomies for hallux rigidus. *Clin Podiatr Med Surg* 2011; **28**: 329-44, viii [PMID: 21669342 DOI: 10.1016/j.cpm.2011.03.002]
- 61 **Cavolo DJ**, Cavallaro DC, Arrington LE. The Watermann osteotomy for hallux limitus. *J Am Podiatry Assoc* 1979; **69**: 52-57 [PMID: 759481]
- 62 **Feldman KA**. The Green-Watermann procedure: geometric analysis and preoperative radiographic template technique. *J Foot Surg* 1992; **31**: 182-185 [PMID: 1645006]
- 63 **Dickerson JB**, Green R, Green DR. Long-term follow-up of the Green-Watermann osteotomy for hallux limitus. *J Am Podiatr Med Assoc* 2002; **92**: 543-554 [PMID: 12438500]
- 64 **Youngswick FD**. Modifications of the Austin bunionectomy for treatment of metatarsus primus elevatus associated with hallux limitus. *J Foot Surg* 1982; **21**: 114-116 [PMID: 7096906]
- 65 **Giannini S**, Ceccarelli F, Faldini C, Bevoni R, Grandi G, Vannini F. What's new in surgical options for hallux rigidus? *J Bone Joint Surg Am* 2004; **86-A** Suppl 2: 72-83 [PMID: 15691111]
- 66 **Oloff LM**, Jhala-Patel G. A retrospective analysis of joint salvage procedures for grades III and IV hallux rigidus. *J Foot Ankle Surg* 2008; **47**: 230-236 [PMID: 18455670 DOI: 10.1053/j.jfas.2008.02.001]
- 67 **Bryant AR**, Tinley P, Cole JH. Plantar pressure and joint motion after the Youngswick procedure for hallux limitus. *J Am Podiatr Med Assoc* 2004; **94**: 22-30 [PMID: 14729987]
- 68 **Ronconi P**, Monachino P, Baleanu PM, Favilli G. Distal oblique osteotomy of the first metatarsal for the correction of hallux limitus and rigidus deformity. *J Foot Ankle Surg* 2000; **39**: 154-160 [PMID: 10862386 DOI: 10.1016/S1067-2516(00)80016-2]
- 69 **Gonzalez JV**, Garrett PP, Jordan MJ, Reilly CH. The modified Hohmann osteotomy: an alternative joint salvage procedure for hallux rigidus. *J Foot Ankle Surg* 2004; **43**: 380-388 [PMID: 15605050 DOI: 10.1053/j.jfas.2004.09.007]
- 70 **Malerba F**, Milani R, Sartorelli E, Haddo O. Distal oblique first metatarsal osteotomy in grade 3 hallux rigidus: a long-term followup. *Foot Ankle Int* 2008; **29**: 677-682 [PMID: 18785417 DOI: 10.3113/FAI.2008.0677]
- 71 **Kissel CG**, Mistretta RP, Unroe BJ. Cheilectomy, chondroplasty, and sagittal "Z" osteotomy: a preliminary report on an alternative joint preservation approach to hallux limitus. *J Foot Ankle Surg* 1995; **34**: 312-318 [PMID: 7550198 DOI: 10.1016/S1067-2516(09)80066-5]
- 72 **Viegas GV**. Reconstruction of hallux limitus deformity using a first metatarsal sagittal-Z osteotomy. *J Foot Ankle Surg* 1998; **37**: 204-211; discussion 261-262 [PMID: 9638545]
- 73 **Dermer R**, Goss K, Postowski HN, Parsley N. A plantar-flexor-shortening osteotomy for hallux rigidus: a retrospective analysis. *J Foot Ankle Surg* 2005; **44**: 377-389 [PMID: 16210158 DOI: 10.1053/j.jfas.2005.07.010]
- 74 **Selner AJ**, Bogdan R, Selner MD, Bunch EK, Mathews RL, Riley J. Tricorrectional osteotomy for the correction of late-stage hallux limitus/rigidus. *J Am Podiatr Med Assoc* 1997; **87**: 414-424 [PMID: 9308308]

P- Reviewers: Chen CY, Laborde M, van den Bekerom MPJ, Volker S
S- Editor: Qi Y **L- Editor:** A **E- Editor:** Liu SQ





百世登

Baishideng®

Published by **Baishideng Publishing Group Co., Limited**

Flat C, 23/F., Lucky Plaza, 315-321 Lockhart Road,

Wan Chai, Hong Kong, China

Fax: +852-65557188

Telephone: +852-31779906

E-mail: bpgoffice@wjgnet.com

<http://www.wjgnet.com>

